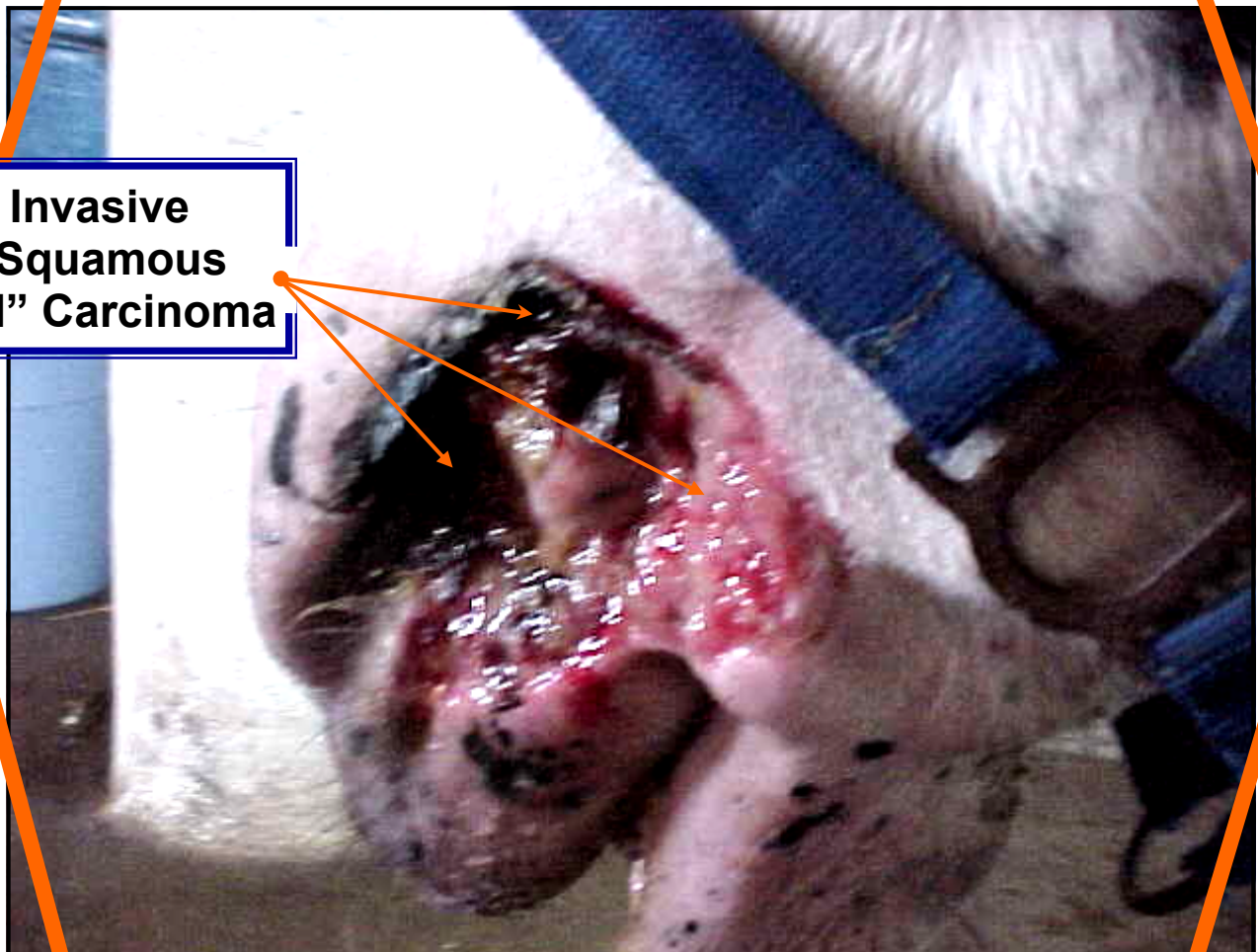


Equine - Invasive Squamous Cell Carcinoma of the Jaw Area

Picture taken 2 days after the 1st. Ig2000™ Treatment 01-28

Invasive
“Squamous
Cell” Carcinoma



Note: the Cancer had metastasized previous to any Ig2000™ therapies