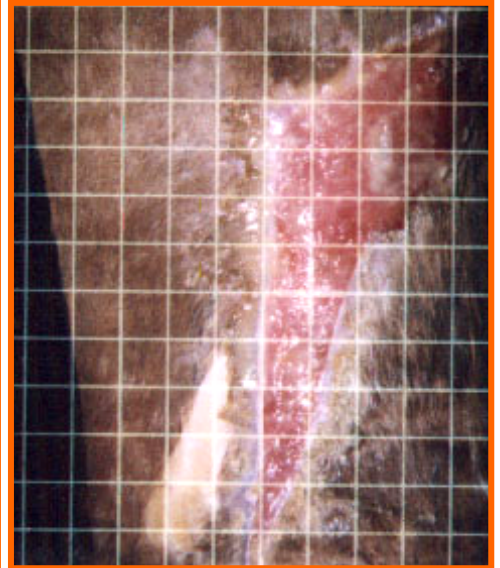
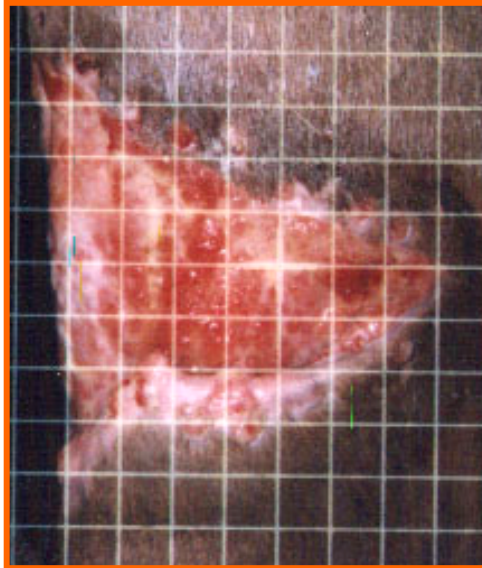
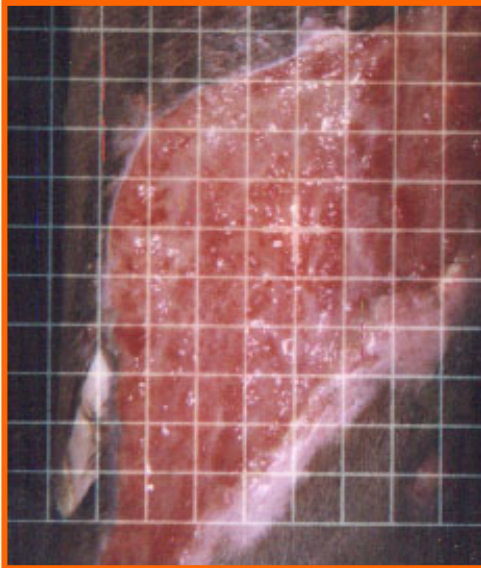


EQUINE vs. ELECTRONIC FENCE

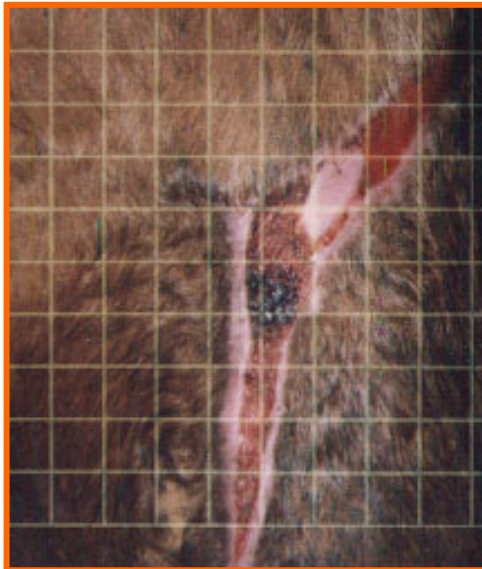
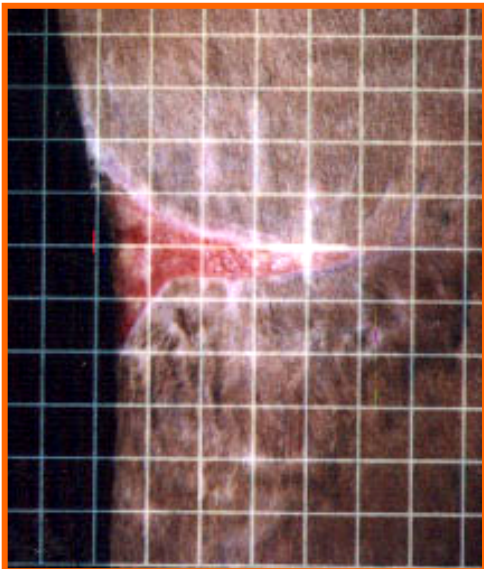
Large “spiraling” leg wound caused by an electric wire fence
Ig2000™ Laser Therapy began the same day the injury occurred



Subject #4 Before Therapy 11-22

2nd Angle Before Therapy 11-22

Subject #4 at 28 days 12-20



2nd Angle 12-20

Subject #4 01-10

Subject #4 Resolution 01-20

**Wound was treated with the Ig2000 only - 20 Treatments
over a 50 day period - No Proud Flesh formed
No antibiotics, topicals or gels were administered or applied
Good wound contracture and tissue integrity maintained
Minimal to no scarring - Hair regrowth natural color**