
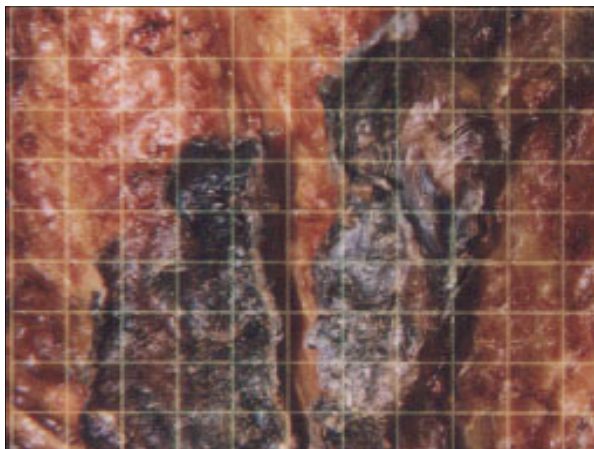


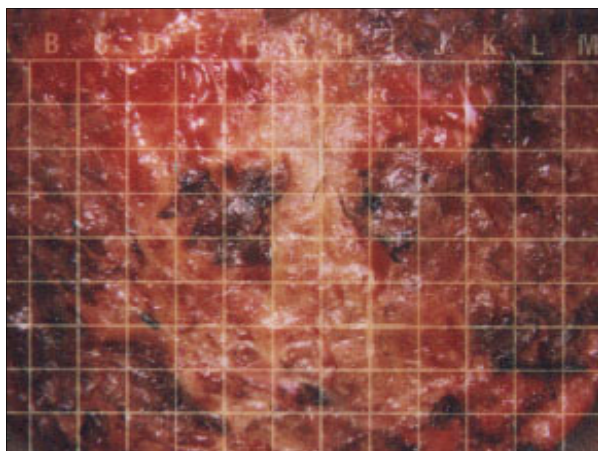
**Equine - Large, deep fence post Puncture Wound to the Breast - Treatment with the Ig2000™ began the second day after the injury occurred**




**Subject #3 Before Therapy 01-26**



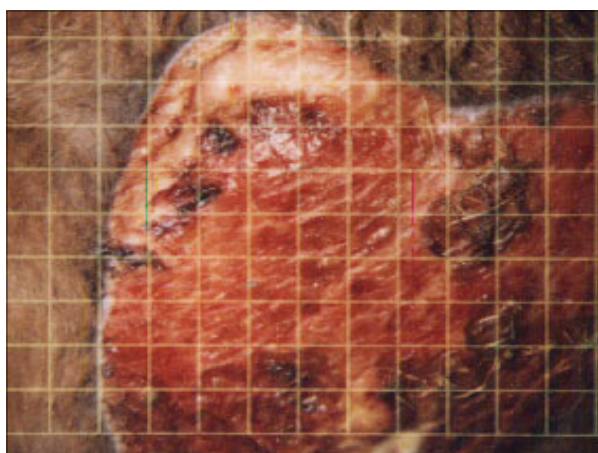
**Subject #3 02-04**




**Subject #3 02-09**



**Subject #3 02-14**



**Subject #3 02-18**



**Zoom x 1.5**

**Subject #3 After 11 Therapies 02-21**

**Wound was treated with the Ig2000 only - No Proud Flesh Formed  
No antibiotics, topicals or gels were used - Good wound closure and  
tissue integrity - Minimal to no scarring - Hair regrowth natural color**