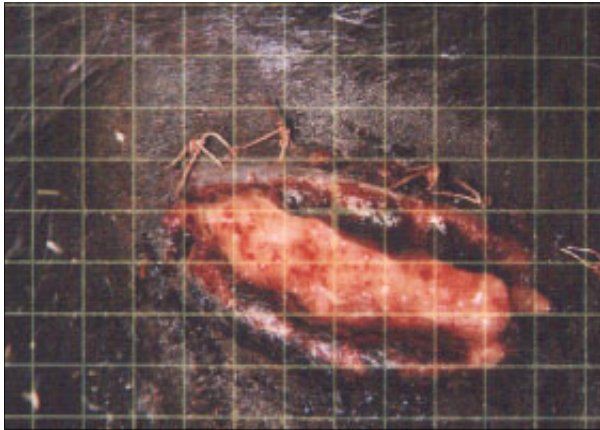
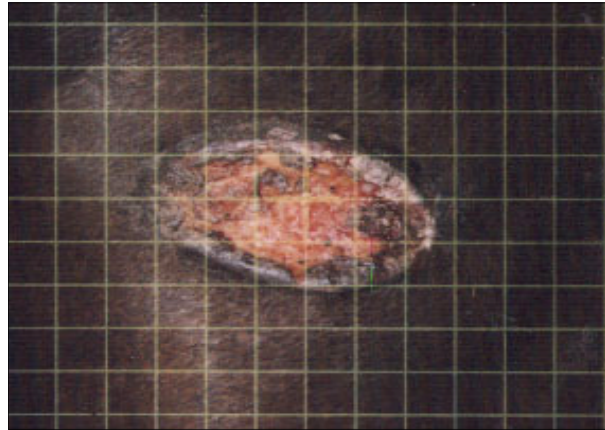


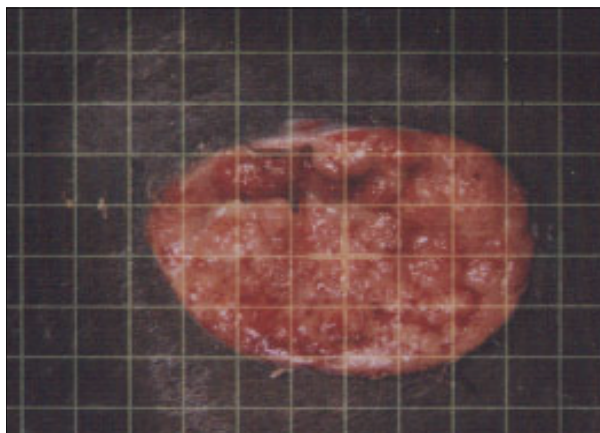**Equine - Two week old Breast Wound
Sutures Failed - Proud Flesh had formed - Ig2000™
treatments began two weeks *after* sutures failed**



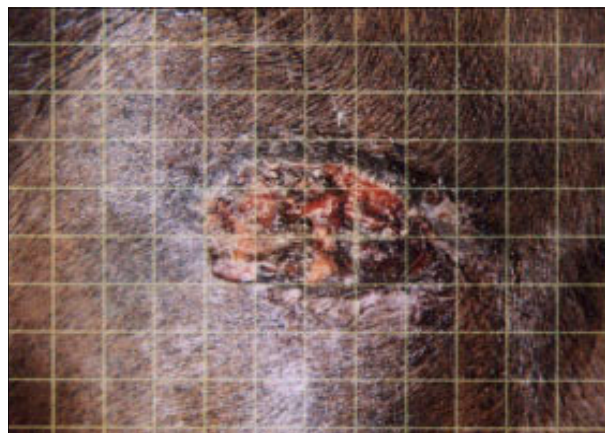
Subject #1 Before Therapy 03-09



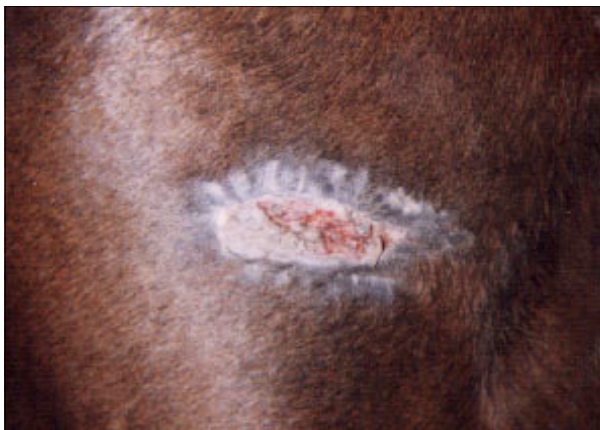Subject #1 03-13



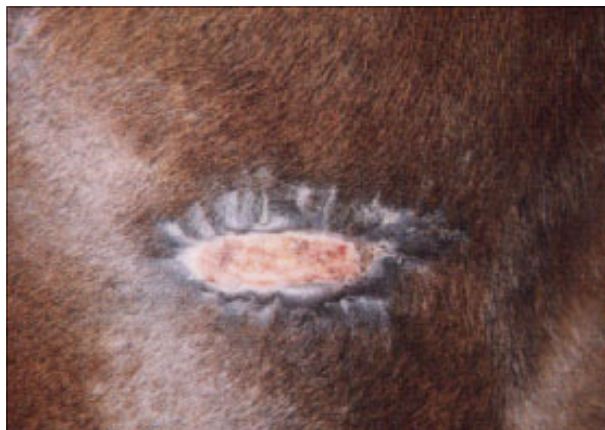Subject #1 03-17



Subject #1 03-22



Subject #1 03-27



Subject #1 After 9 Therapies 03-29

**Wound was treated with the Ig2000 only - Proud Flesh denatured -
No antibiotics, topicals or gels were used - Good wound closure and
tissue integrity - Minimal scarring - Hair regrowth natural color**